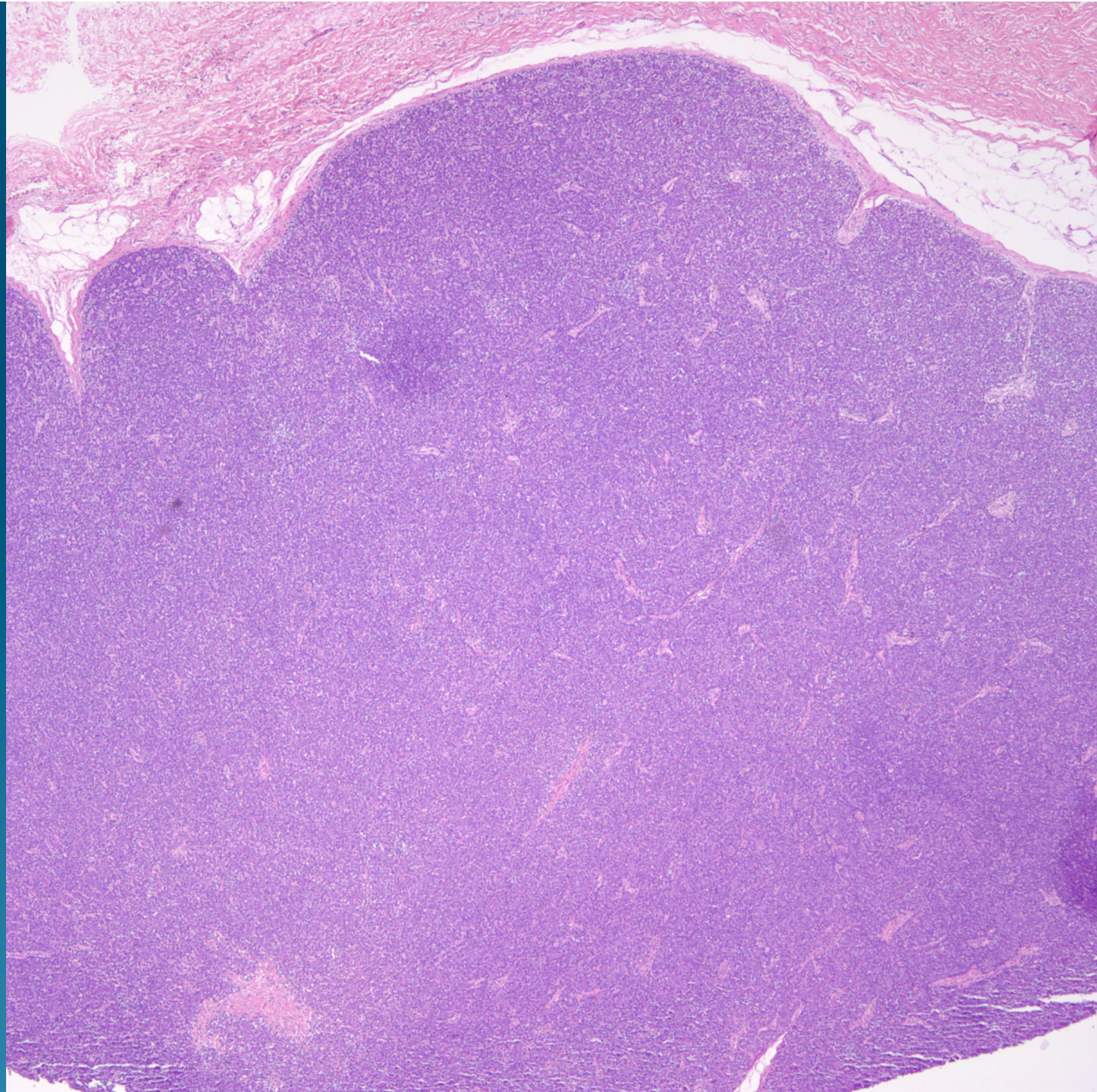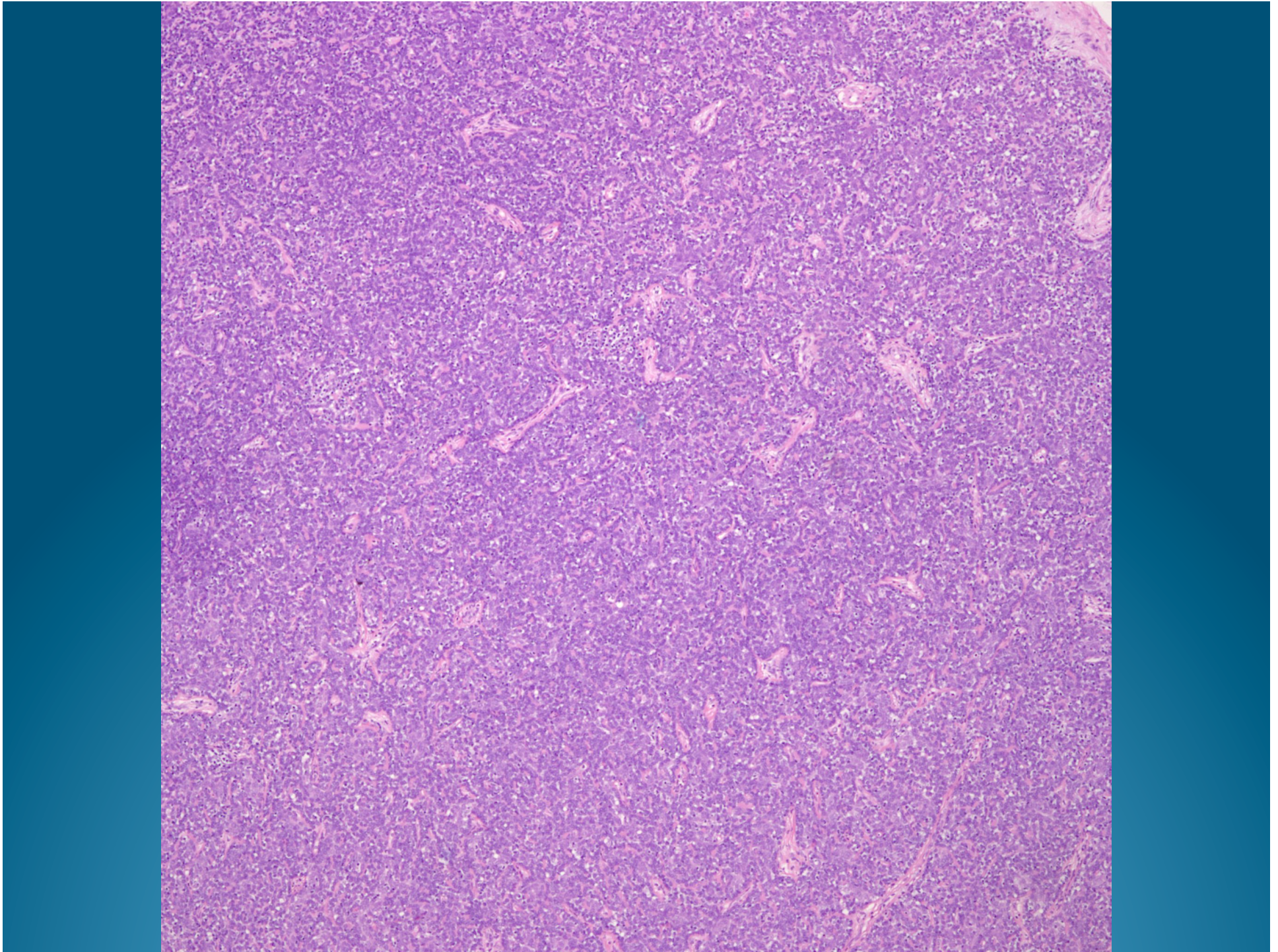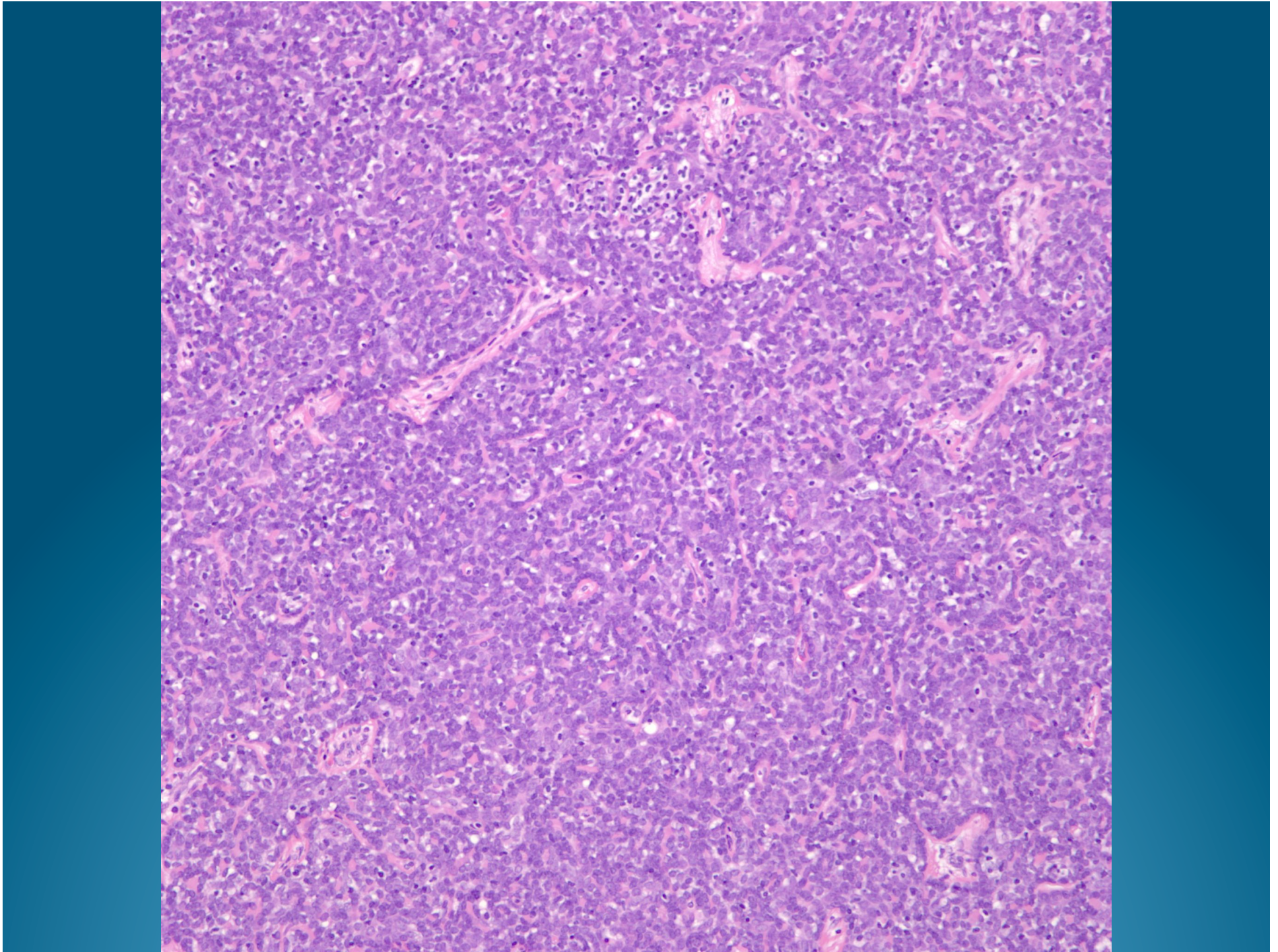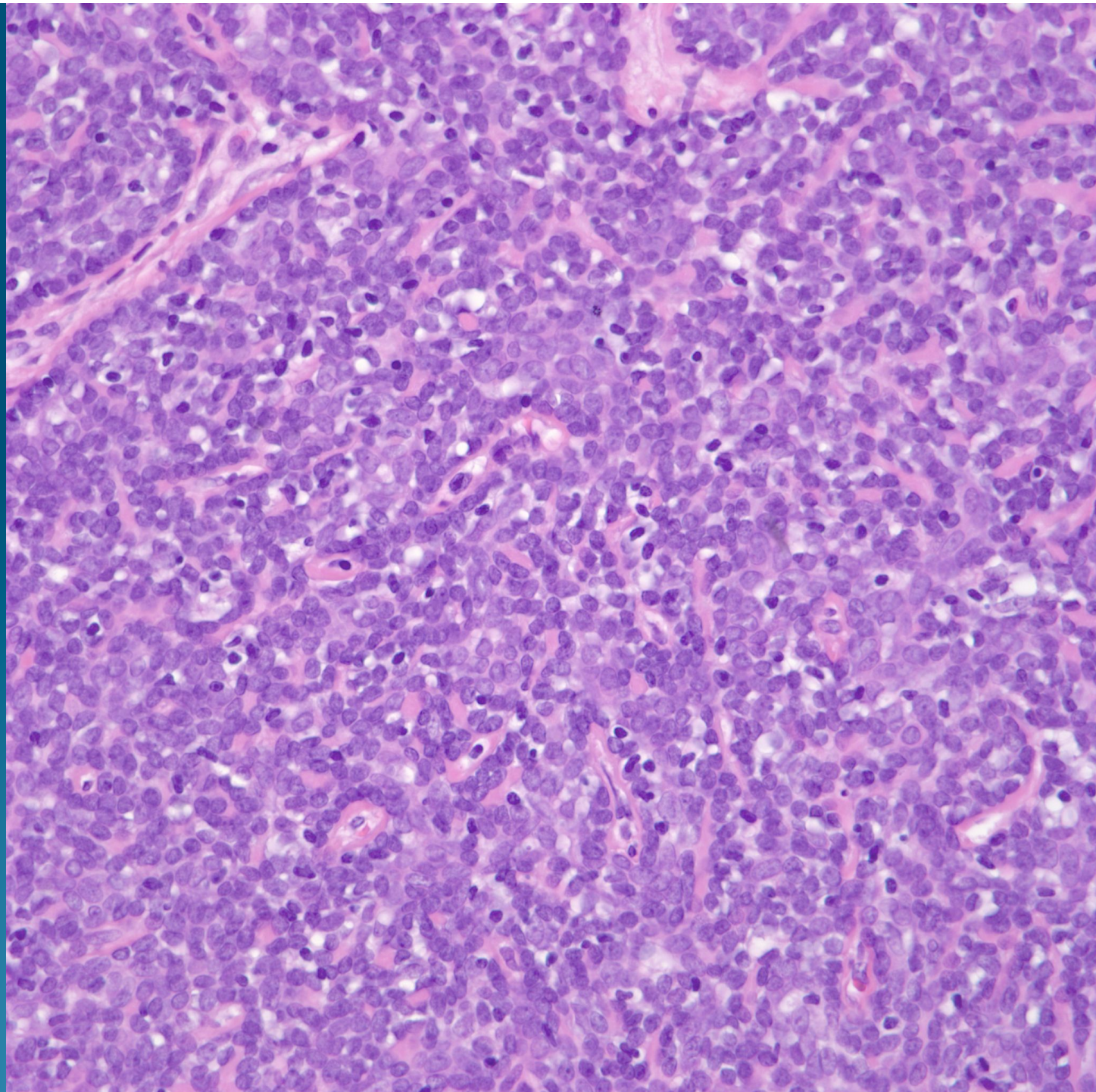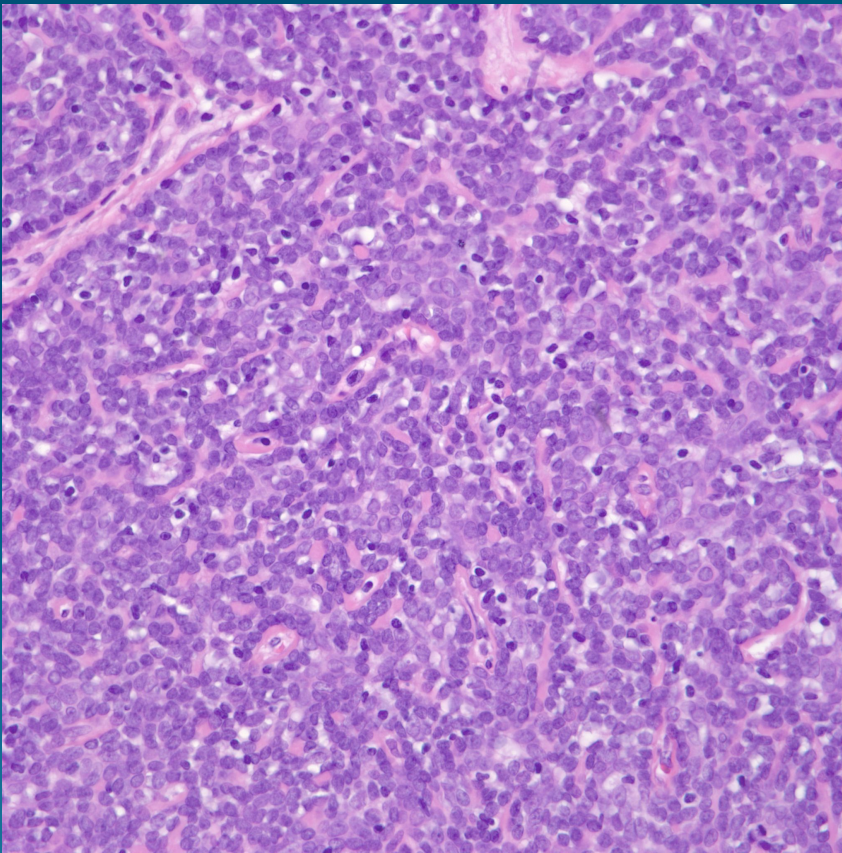


What is the best diagnosis?

- A. Nodular hidradenoma
- B. Tricholemmoma
- C. Pilomatricoma
- D. Glomus tumor
- E. Eccrine spiradenoma

Eccrine Spiradenoma

Pearls



- Circumscribed dermal nodule, unattached to epidermis
- Small basaloid cells with minimal variation admixed with small lymphocytes
- Hyalinized basement membrane surrounding larger nests